



## **Motor unit territories in human genioglossus estimated with multichannel intramuscular electrodes**

Downloaded from: <https://research.chalmers.se>, 2026-04-04 20:26 UTC

Citation for the original published paper (version of record):

Luu, B., Muceli, S., Saboisky, J. et al (2018). Motor unit territories in human genioglossus estimated with multichannel intramuscular electrodes. *Journal of Applied Physiology*, 124(3): 664-671.  
<http://dx.doi.org/10.1152/jappphysiol.00889.2017>

N.B. When citing this work, cite the original published paper.

## RESEARCH ARTICLE

# Motor unit territories in human genioglossus estimated with multichannel intramuscular electrodes

Billy L. Luu,<sup>1\*</sup> Silvia Muceli,<sup>2\*</sup> Julian P. Saboisky,<sup>1\*</sup>  Dario Farina,<sup>2</sup>  Martin E. Héroux,<sup>1</sup>  
 Lynne E. Bilston,<sup>1</sup> Simon C. Gandevia,<sup>1</sup> and  Jane E. Butler<sup>1</sup>

<sup>1</sup>Neuroscience Research Australia, Randwick, and University of New South Wales, Sydney, Australia; and

<sup>2</sup>Neurorehabilitation Systems Research Group, Clinic for Trauma Surgery, Orthopaedics and Plastic Surgery, University Medical Center Göttingen, Georg-August University, Göttingen, Germany

Submitted 28 September 2017; accepted in final form 5 December 2017

**Luu BL, Muceli S, Saboisky JP, Farina D, Héroux ME, Bilston LE, Gandevia SC, Butler JE.** Motor unit territories in human genioglossus estimated with multichannel intramuscular electrodes. *J Appl Physiol* 124: 664–671, 2018. First published December 14, 2017; doi:10.1152/jappphysiol.00889.2017.—The discharge patterns of genioglossus motor units during breathing have been well-characterized in previous studies, but their localization and territories are not known. In this study, we used two newly developed intramuscular multichannel electrodes to estimate the territories of genioglossus motor units in the anterior and posterior regions of the muscle. Seven healthy men participated. Each electrode contained fifteen bipolar channels, separated by 1 mm, and was inserted percutaneously below the chin, perpendicular to the skin, to a depth of 36 mm. Single motor unit activity was recorded with subjects awake, supine, and breathing quietly through a nasal mask for 180 s. Motor unit territories were estimated from the spike-triggered averages of the electromyographic signal from each channel. A total of 30 motor units were identified: 22 expiratory tonic, 1 expiratory phasic, 2 tonic, 3 inspiratory tonic, and 2 inspiratory phasic. Motor units appeared to be clustered based on unit type, with peak activities for expiratory units predominantly located in the anterior and superficial fibers of genioglossus and inspiratory units in the posterior region. Of these motor unit types, expiratory tonic units had the largest estimated territory, a mean 11.3 mm (SD 1.9). Estimated territories of inspiratory motor units ranged from 3 to 6 mm. In accordance with the distribution of motor unit types, the estimated territory of genioglossus motor units varied along the sagittal plane, decreasing from anterior to posterior. Our findings suggest that genioglossus motor units have large territories relative to the cross-sectional size of the muscle.

**NEW & NOTEWORTHY** In this study, we used a new multichannel intramuscular electrode to address a fundamental property of human genioglossus motor units. We describe the territory of genioglossus motor units in the anterior and posterior regions of the muscle and show a decrease in territory size from anterior to posterior and that expiratory-related motor units have larger estimated territories than inspiratory-related motor units.

breathing; respiratory; tongue; upper airway

## INTRODUCTION

The tongue is an important structure in the upper airway as it is involved in regulation of airflow through the pharynx during breathing (2, 3, 11, 12, 22, 28). In humans, it comprises four intrinsic muscles that alter the shape and effect the movement of the tongue blade and four extrinsic muscles that control the position of the tongue in the upper airway. Of the extrinsic muscles, the genioglossus is the most studied as it forms a large portion of the base of the tongue (31) and, as the primary protruder of the tongue (23), it also facilitates the dilation and/or prevents the collapse of the upper airway during inspiration.

Several studies have characterized human genioglossus motor unit behavior during breathing (e.g., 1, 24, 32) using intramuscular electromyographic (EMG) recordings to show distinct populations of units that discharge tonically or phasically during different stages of the respiratory cycle. However, information relating to the spatial distribution of the different types of genioglossus motor units and the size of their territories [i.e., the electrophysiological cross-section occupied by the muscle fibers innervated by a single motoneuron (29)] is lacking. There is some electrophysiological evidence from multiunit EMG recordings that suggests that phasic activity is localized in the genioglossus (9). This view is supported by two studies that show the genioglossus exhibits focal movements during breathing (8) and is composed of oblique (deep relative to the skin) and horizontal (superficial) compartments that are innervated by separate branches of the hypoglossal nerve (19). Nevertheless, the extent to which localized activity is possible will depend largely on the size of the territories of the motor units.

Assessing motor unit territories in human muscles has been difficult. Previous techniques that measure the spread of action potentials across the muscle fibers were either developed for larger and more accessible limb muscles (6, 15, 33) or required constant activation of a low-threshold motor unit (29). In the present study, we investigated genioglossus motor units using a new multielectrode array embedded on a thin, filmlike structure (20). This arrangement allowed unbiased sampling of single motor unit activity over a relatively large area, spanning both the horizontal and oblique fibers of the genioglossus, without restricting the movement or activation of the tongue during normal breathing. The aim of this study was to describe in humans the distribution of motor unit types in the anterior

\* B. L. Luu, S. Muceli, and J. P. Saboisky made equal contributions to this paper.

Address for reprint requests and other correspondence: J. E. Butler, Neuroscience Research Australia, Barker St., Randwick, NSW 2031, Australia (e-mail: j.butler@neura.edu.au).

and posterior regions of the human genioglossus and to estimate the size of their territories.

## METHODS

Seven healthy men with a mean age of 38.4 yr (SD 11.6, range 26–62 yr) participated in these experiments. Their body mass index ranged from 20.0 to 26.2 kg/m<sup>2</sup>, and apnea-hypopnea index ranged from 0 to 8.0 events per hour sleep. Subjects gave their informed consent in writing. All procedures were approved by the Human Research Ethics Committee at the University of New South Wales and conducted in accordance with the Declaration of Helsinki (2008).

**Experimental setup.** Experiments were conducted with the subject supine and breathing quietly through a nasal mask (Fig. 1). Subjects had their mouths closed and remained awake throughout the study. To standardize the head and neck position across participants, the head was supported underneath by a memory-foam pillow and oriented based on two angular measurements: 1) the angle formed by a line drawn from the lateral angle of the eye to the tragus of the ear and horizontal was confined to between 72 and 85°; and 2) the angle formed by a line connecting the tragus to the spinous process of the C7 vertebrae and horizontal was kept between 37 and 48° (as described in Ref. 17).

Respiratory airflow, which was integrated online to obtain tidal volume, was recorded from a pneumotachometer (3700 Series; Hans Rudolph) and differential pressure transducer (DP45-16; Validyne Engineering) connected to the nasal mask.

EMG activity of the genioglossus was recorded using 2 custom thin-film electrode arrays (see Ref. 20). Each electrode array contained 16 oval-shaped, platinum recording surfaces (140 × 40 μm) mounted linearly on a thin film with interelectrode distances of 1 mm (Fig. 1A). EMG activities were recorded with a bipolar configuration with the deepest electrode used as the reference, producing 15 channels per array. A ground plane electrode was placed on the left shoulder. For the flat, fan-shaped genioglossus, both electrode arrays were positioned across the muscle fibers and in the sagittal plane. With the use of a 25-gauge hypodermic needle, an anterior electrode array was inserted perpendicular to the skin ~10 mm below the inner

border of the mental protuberance of the chin and ~3 mm lateral to the midline (Fig. 1B), the approximate center of the left genioglossus in the coronal plane (9). The second, posterior electrode array was inserted ~20 mm below the inner border of the mental protuberance. No discomfort or pain was reported during or after insertion. The tips of the needles were inserted to the maximum depth of 38 mm. Therefore, the deepest EMG channel was ~36 mm from the surface of the skin after accounting for a 1-mm bevel and the position of the reference channel. Ultrasound measurements [Philips iU22, C8–5 (5–8 MHz) transducer] were made before insertion to estimate the depth of the electrodes, with the ultrasound probe held perpendicular to and with minimal pressure against the skin.

Data were acquired with a multichannel amplifier (EMG-USB2; OT Bioelettronica, Torino, Italy), band-pass filtered (100–4,400 Hz), amplified (2,000–10,000×), and sampled at 10,240 Hz using a 12-bit analog-to-digital converter and stored on a computer for analysis. Some channels were designated as faulty, either by the manufacturer before the study or if the EMG signal was dominated by electrical noise.

**Motor unit classification.** Raw EMG signals recorded during 180 s of quiet breathing were decomposed using EMGLAB (18) to identify individual motor unit action potentials in the genioglossus. Briefly, EMGLAB uses a template-matching algorithm to detect motor units automatically based on the shape of the motor unit action potentials. In this study, each channel was decomposed separately. Since the waveform shape of a motor unit action potential may change over time, signals were analyzed in intervals of ~2 s with increments of 0.5 s. Automatic decomposition was applied first. The accuracy of the algorithm was then verified manually by an investigator using the graphical interface of EMGLAB (1) to inspect the series of discharges of a single motor unit and 2) to subtract the template waveform of the motor unit from the raw EMG signal to create a residual signal. This process was repeated for each motor unit identified from the same channel until the residual signal, after all motor unit templates were subtracted, was comparable in power with the baseline noise of the raw signal, indicating all motor unit activity had been accounted for. In cases where it appeared that the same motor unit was detected in adjacent channels (see Fig. 2), their discharge patterns were compared to determine whether these adjacent motor units were unique from the first unit.

Motor units were then classified into one of five types based on their discharge pattern during the respiratory cycle (24). Purely tonic units exhibited no clear modulation in instantaneous discharge frequency during breathing. Inspiratory or expiratory tonic units discharged continuously but modulated their discharge rate so that peaks occurred during inspiration or expiration, respectively. Inspiratory or expiratory phasic units were only activated during one phase of the respiratory cycle and were classified based on whether their peak activity occurred during inspiration or expiration. Four motor units were identified that displayed sporadic bursts of activity that did not correlate with respiratory activity and were excluded from further analysis.

**Measurements and analysis.** Classified motor unit data were exported from EMGLAB to Spike2 (v7.12; Cambridge Electronic Design, Cambridge, United Kingdom) and measured using a custom script. To illustrate the activation pattern and peak discharge frequencies of genioglossus motor units during breathing, a time and frequency plot was constructed from data averaged across three consecutive breaths, with discharge times expressed relative to the onset of inspiratory flow (26). The onset times of phasic units were measured at the first spike discharge for each breath, and the onset discharge frequencies were calculated as the instantaneous frequency from the first interspike interval. The onset times of inspiratory and expiratory tonic units were measured at the first increase in discharge rate above the tonic discharge frequency, which also corresponded to the onset discharge frequency. Offset times for phasic units were calculated at the last spike discharge for each breath and, for inspiratory and

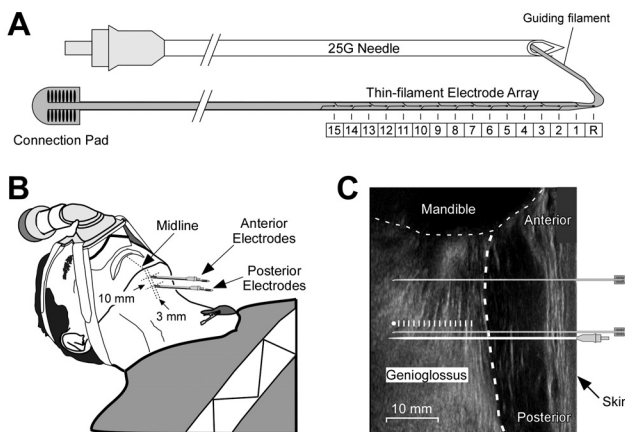


Fig. 1. Experimental setup. **A:** each electrode array was mounted on a U-shaped filament (20 μm thick) that had a total length of 68.1 mm. A needle was used to insert the electrode array into the genioglossus with the recording part of the filament (420 μm wide) positioned outside of the needle and a narrower (100 μm wide) guiding portion threaded through the needle. The electrode array contained 15 bipolar channels (1–15), spaced 1 mm apart, and a reference channel (R). G, gauge. **B:** needle insertion points. The anterior electrode was inserted perpendicular to the skin 10 mm below the mental protuberance of the chin. The ground electrode was placed on the left shoulder. **C:** an ultrasound image depicting the depth and location of both electrode arrays in the genioglossus. Graduated lines indicate the depths of each channel with the reference electrode represented by the circle.

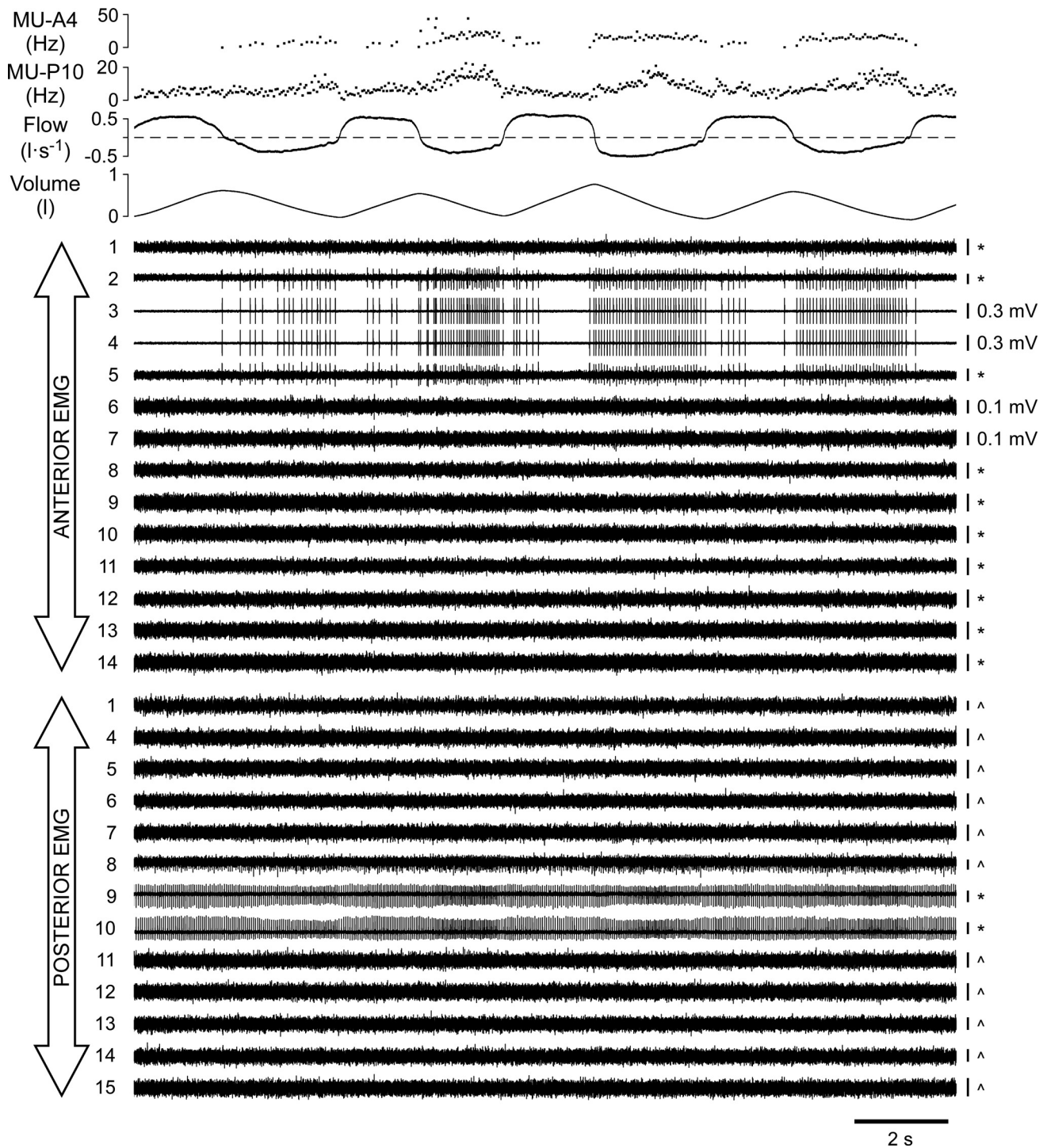


Fig. 2. Raw data. Individual participant data of anterior and posterior electromyographic (EMG) signals in the genioglossus during quiet breathing. Increases in lung volume and a positive airflow represent periods of inspiration. A single expiratory phasic motor unit (MU-A4) was recorded from the 4th anterior EMG channel with its instantaneous discharge frequency shown in the top trace. A separate expiratory tonic unit (MU-P10) was recorded simultaneously from the 10th posterior EMG channel, and its discharge frequency is shown in the 2nd trace. Channel 1 was the deepest recording for the anterior and posterior electrode arrays, at an estimated depth of 13 and 11 mm, respectively, in the genioglossus. All EMG channels were optimized along the y-axis, and faulty channels were removed. \*0.05-mV and ^0.02-mV ranges.

expiratory tonic units, when the increased discharge rate returned to the tonic discharge frequency. Peak discharge frequencies were determined from a moving average (200-ms window) of the instantaneous discharge frequency.

To determine the dispersion of electrical activity throughout the muscle for a motor unit, averages of the raw EMG signals for both

anterior and posterior electrodes were triggered from the discharge times of the motor unit over 180 s, producing 30 (15 anterior and 15 posterior) spike-triggered average waveforms of 35-ms duration (10-ms pretrigger). Spike-triggered averages between the anterior and posterior electrodes were used to determine whether a motor unit spans these 2 regions of the muscle. The territory of a motor unit in

the sagittal plane (measured as the electrophysiological cross-sectional territory in millimeters) was estimated using only the 15 triggered averages from 1 electrode, the same electrode array from which the unit was recorded. With an interelectrode distance of 1 mm, the territory of the motor unit was calculated as 1 less than the total number of consecutive channels with peaks that exceeded the pretrigger baseline mean by 4 SD (15). In 7 out of 30 motor units, the spike-triggered averages produced peaks in nonadjacent channels that crossed the 4-SD threshold. For these units, if the shape of the averaged waveform was considered to resemble a motor unit action potential, as verified visually by 3 of the investigators of the study, then it was included in the total territory of the motor unit. Peak-to-peak amplitudes of the spike-triggered averages were normalized as a percentage of the maximum amplitude across all channels. This process was repeated for each motor unit.

As this is primarily a descriptive study, no formal statistical analyses were planned. However, a Student's *t*-test was used to compare territory size between the expiratory and inspiratory motor units (SigmaPlot 12.0). Motor unit territories for the motor units are reported as means (SD).

## RESULTS

Genioglossus muscle activity was recorded during quiet breathing in six out of seven participants. For the remaining subject, bursts of motor unit activity were present during a voluntary swallow, but no clear muscle activity was observed during quiet breathing. A typical example of raw EMG recordings is shown for an individual participant in Fig. 2. For this participant, a single motor unit can be seen across several adjacent anterior channels while a different motor unit is visible in the posterior channels.

A total of 30 motor units were identified across participants based on their shape and discharge pattern, with an average of 2,347.8 (SD 1,562.8) spike discharges per motor unit and a range of 486–4,655 spikes. The mean motor unit yield per participant was 5.0 (SD 2.6; range 2–9 units) for the 6 participants. Figure 3 shows the onset times and discharge frequencies for all motor units relative to inspiratory time. A large proportion of the motor units were classified as expiratory, with 22 expiratory tonic units and 1 expiratory phasic unit. The majority (16 out of 22) of expiratory tonic units were recruited during late inspiration, with the earliest increase in discharge rate occurring at 65.5% of inspiratory time. The mean tonic frequency for all expiratory tonic units was 15.7 Hz (SD 4.8), which increased to 17.4 Hz (SD 5.1) at the onset of recruitment and reached a peak of 23.3 Hz (SD 5.5) during expiration. The mean offset frequency was 18.3 Hz (SD 4.4). The remaining units were classified as being 2 tonic units, 3 inspiratory tonic units, and 2 inspiratory phasic units. Of the 23 expiratory motor units, 20 (87%) were recorded from the anterior electrodes. All 5 inspiratory motor units were recorded from the posterior electrodes.

**Motor unit territories.** The spike-triggered averages for 2 expiratory motor units are shown in Fig. 4. The expiratory tonic unit in Fig. 4A was recorded in the anterior electrode and had a large territory, spanning 14 channels with a territory of 13 mm. Several posterior channels, which were inserted 10 mm parallel to the anterior electrodes, also showed peaks that crossed the 4-SD threshold in the spike-triggered averages. In contrast, the expiratory phasic unit in Fig. 4B had a smaller territory of 7 mm anteriorly in the genioglossus with no peaks

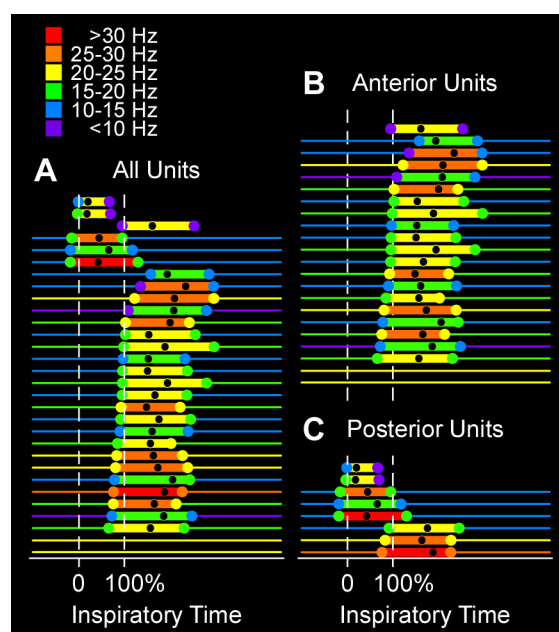


Fig. 3. Time and frequency plots. The activation patterns for all motor units (A) were averaged over 3 typical breaths. Motor units were clustered based on unit type and then ordered from top to bottom based on the slowest onset times relative to inspiration. Vertical, dashed lines mark the beginning and end of inspiration. Phasic motor units are shown in the top 3 traces. The length of each thick horizontal line indicates the period of activation for phasic motor units or the period of modulation for inspiratory and expiratory tonic units. The color of each thick line represents the peak discharge frequency, and its timing is indicated by the black circle. Onset and offset discharge frequencies are indicated by colored circles. Thin horizontal lines show the tonic discharge frequency for motor units that were active throughout the respiratory cycle. The color legend shows frequency bands with an exclusive low range and an inclusive high range. Data from A were split to show motor units recorded from the anterior (B) and posterior (C) electrodes.

that crossed the 4-SD threshold in the triggered averages for the posterior channels.

The territories of all thirty motor units are shown in Fig. 5A. Half of the motor units had significant peaks in the spike-triggered averages in both anterior and posterior electrodes. The mean territory for motor units recorded in the anterior electrodes was 11.3 mm (SD 1.9). Motor units recorded from the posterior electrodes had a mean territory of 6.5 mm (SD 2.2). Coincidentally, the mean territory for expiratory tonic units was also 11.3 mm (SD 1.9), whereas the single expiratory phasic unit had a territory of 7 mm. The combined phasic and tonic expiratory units had territories that were significantly larger [11.1 mm (SD 2.1), range 7–14 mm] than the five inspiratory motor units [5.2 mm (SD 1.3), range 3–6 mm;  $P < 0.001$ ].

Figure 5B shows the spatial distribution of the peak activity for each motor unit in the genioglossus. Motor units appeared to be clustered based on unit type. Expiratory tonic units were located in the superficial fibers and predominantly in the anterior region of the muscle. The peak activity of the single expiratory phasic unit was also recorded in the anterior region of genioglossus but from deeper muscle fibers. Peak activities for inspiratory motor units were located posteriorly and primarily in the deeper fibers of genioglossus.

Estimated territory size relative to peak activity is shown for each motor unit in Fig. 6 with data centered on the channel

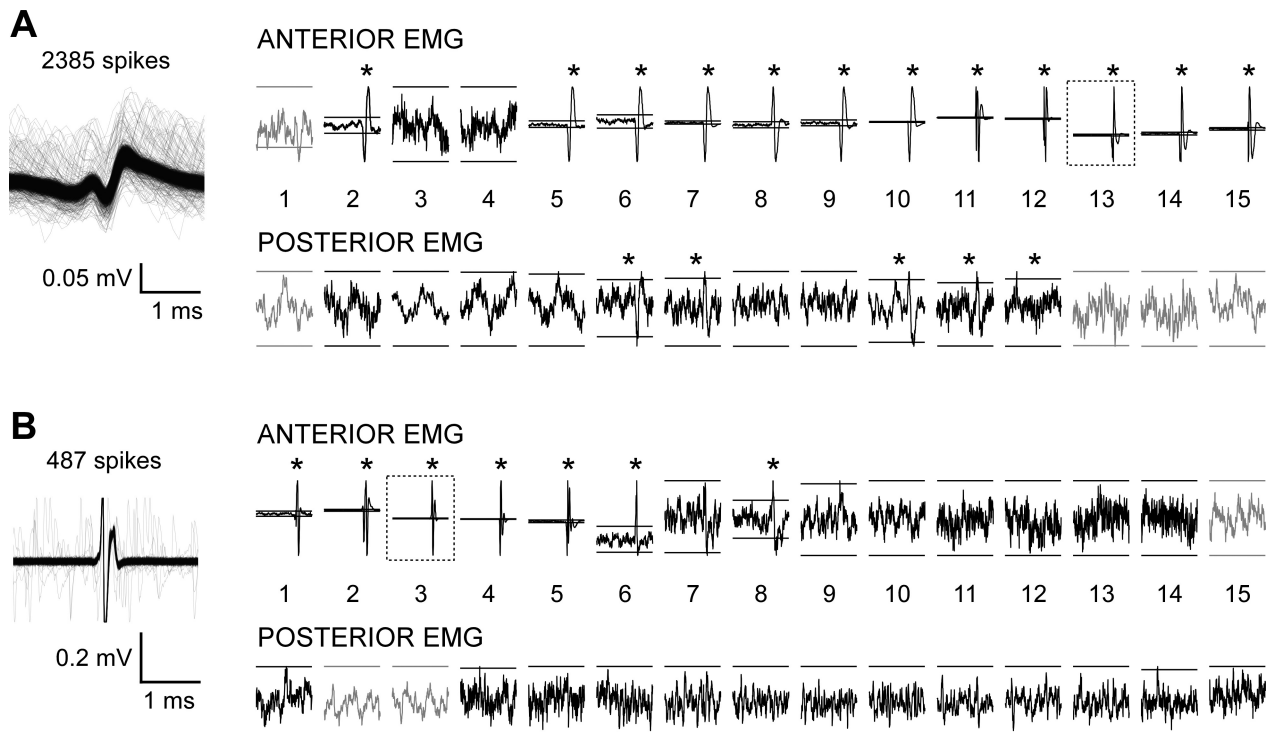


Fig. 4. Spike-triggered averages. Two motor units with their action potentials are superimposed on the *left*, and the averaged electromyographic (EMG) signals triggered from the spike discharge of each motor unit are shown on the *right* (35-ms epochs, 10-ms pretrigger). In *A*, an expiratory tonic unit was extracted from the 13th anterior channel (peak-to-peak amplitude: 0.07 mV), and in *B*, an expiratory phasic unit was extracted from the 3rd anterior channel (peak-to-peak amplitude: 0.49 mV), as shown by the dashed boxes. Channel 1 was deepest in the genioglossus relative to the skin. The scale for the y-axis has been optimized for all channels. The maximum peak-to-peak amplitudes across EMG channels on the posterior electrode were 0.01 mV in *A* and 0.02 mV in *B*. Horizontal bars indicate  $\pm 4$  SD from the pretrigger mean. Channels with peaks that crossed the 4-SD threshold are indicated by an asterisk, and faulty channels are shown in gray.

with the greatest amplitude. Raw data for expiratory tonic and all inspiratory motor units show no consistent trend between low- and higher-amplitude motor units and estimated territory size (Fig. 6A). When amplitude was normalized to maximum, expiratory tonic units showed a large variability in the decrease in amplitude from the peak (Fig. 6B). This variability in amplitude was not obvious in inspiratory motor units. The horizontal, dashed line in Fig. 6B shows a more conservative estimate of territory based on a significance level set at  $>20\%$  of maximum for normalized peak-to-peak amplitudes (e.g., 13), resulting in an adjusted mean of 3.7 mm (SD 2.4) for expiratory tonic units and an adjusted range of 1–2 mm for inspiratory units.

## DISCUSSION

In this study, we used a recently developed electrode to address a fundamental property of motor units. We describe the electrophysiological cross-sectional distribution and territory of 30 genioglossus motor units using a multichannel intramuscular electrode (20). At the low levels of genioglossus activation recorded during quiet breathing, expiratory-related motor units were recorded predominantly from the anterior region of the muscle, whereas inspiratory-related motor units were recorded from the posterior region. Generally, genioglossus motor units had large territories relative to the cross-sectional size of the muscle, with many motor units spanning the entire length of the multichannel electrode. Of the motor unit types,

expiratory tonic units had the largest average territories, more than double the territory of each of the inspiratory motor units.

Our main finding shows that the estimated territory of genioglossus motor units varies along the sagittal plane, being smaller in the posterior of the muscle. This is in contrast to the increasing gradient for muscle-fiber diameter in the same direction (27), which would normally predict larger territories for the posterior genioglossus given a uniform innervation ratio. It is not clear whether this difference in territory size is related to the functional roles of the genioglossus to dilate the upper airway during breathing and in nonrespiratory tasks such as tongue protrusion and speech, but it does give rise to the potential for task-dependent localized activity. Certainly, the clustering of inspiratory motor units, which had smaller estimated territories, in the posterior region of the genioglossus allows for the small ( $\sim 1$  mm) and focal movements observed in healthy individuals during quiet breathing (4, 8, 17). Moreover, only half of the motor units had spike-triggered averages that crossed the 4-SD threshold in both anterior and posterior electrodes, suggesting that not all genioglossus fibers extend the length of the muscle. This observation is supported by indirect evidence that shows differences in the proportion of type II muscle fibers in the anterior and posterior regions (27) as well as dual bands of motor end-plates in the horizontal compartment that run across the muscle fibers (19). It is also possible that, for the motor units that did not span both regions of genioglossus, the muscle fibers fan out in the transverse

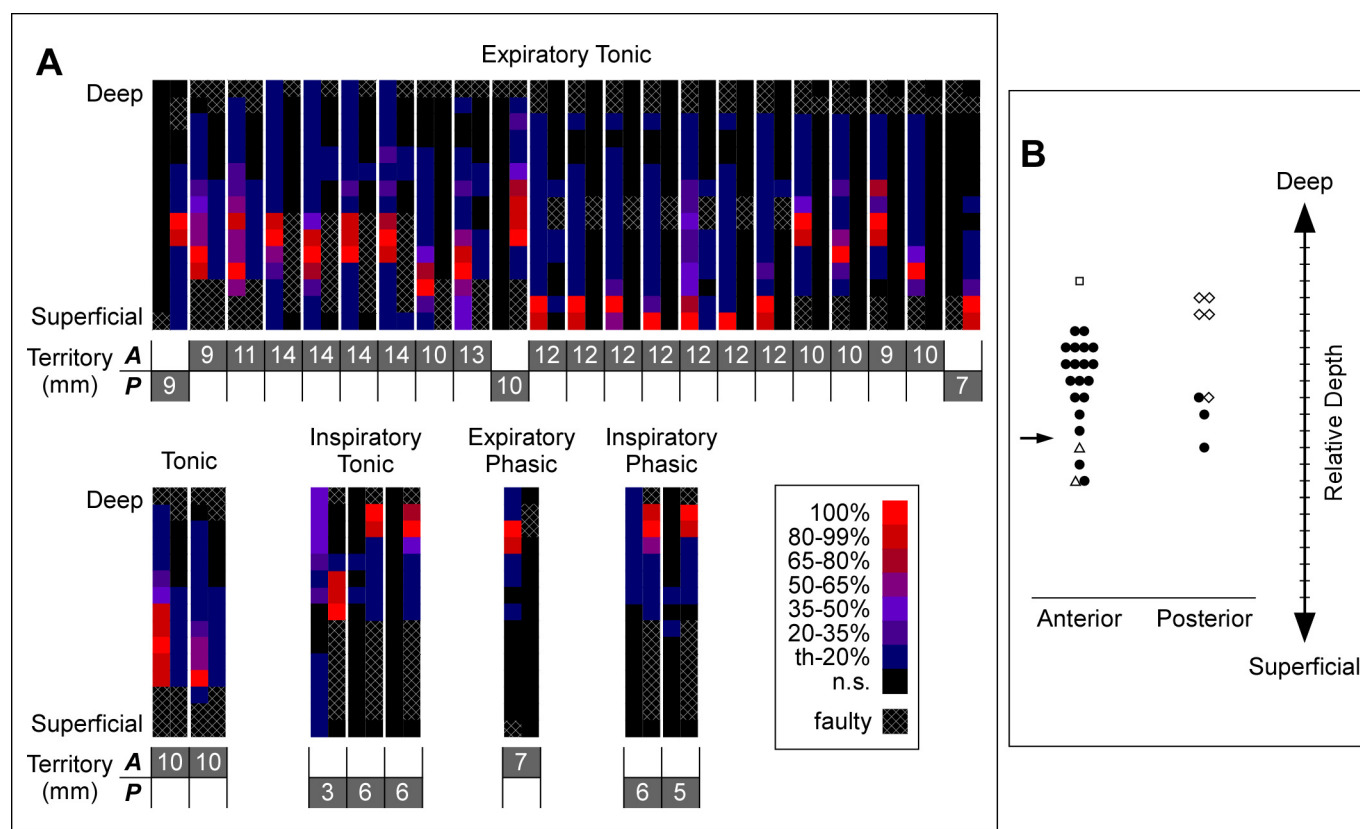


Fig. 5. Motor unit territories. *A*: normalized peak-to-peak amplitudes of the spike-triggered averages. For each motor unit, the anterior (A, left) and posterior (P, right) electrode arrays were paired together with territory sizes shown below. The territory was determined using only channels from the same electrode array from which the unit was recorded. The color legend shows amplitude bands with an exclusive low range and an inclusive high range; th, threshold (4 SD from the baseline mean); n.s., nonsignificant data below threshold. The size of the territory may be underestimated in some cases due to faulty channels or electrode coverage. *B*: relative depth of the maximum peak-to-peak amplitude for each motor unit. The superficial border of the genioglossus (arrow), i.e., closest to the skin, was estimated from ultrasound measurements. Data are shown spread out along the *x*-axis to reveal overlapping data points. Increments of 1 mm along the *y*-axis correspond to the interelectrode distance. ●, Expiratory tonic; □, expiratory phasic; △, tonic; ◇, all inspiratory.

plane away from the posterior electrodes leading to a reduced signal-to-noise ratio when triggering from motor units recorded in the anterior electrode (Fig. 4).

Anteriorly, the larger motor unit territories were not confined to the oblique and horizontal compartment boundaries of the muscle (19). In fact, it appears that most anterior motor units had territories that spanned the entire cross-section of the muscle compared with previous estimates of average muscle thickness that range between 10 and 12 mm measured with ultrasonography (9, 24). This arrangement has obvious benefits for contractions that involve gross movements, such as tongue protrusion or opposing gravity when supine, but it may facilitate coordination of airway dilation as is observed in some individuals who show en bloc movements of the whole tongue during quiet breathing (4).

Although genioglossus motor unit territories were large compared with the total cross-sectional dimensions of the muscle, their absolute sizes fell within the normal range (2–15 mm) reported for healthy muscles of the upper and lower limbs (6, 14, 16, 29, 30). Undoubtedly, the differences in methodology used to determine territory size here, i.e., spike-triggered averages with peaks  $>4$  SD from baseline noise, compared with the predetermined, amplitude-based thresholds used in previous studies, have contributed to the discrepancy in the relative size of motor unit territories. Héroux et al. (15)

similarly reported larger longitudinal territories in the medial gastrocnemius when employing the method of 4 SD from baseline noise for assessing territory size. When genioglossus motor units were evaluated using a criterion of  $>20\%$  of maximum amplitude across channels, territories for inspiratory and expiratory units were reduced to approximately a third of their estimated size. For the genioglossus, we favor the baseline-noise approach for two reasons. First, Fig. 6*B* shows a lot of variability in the amplitude of expiratory tonic units along the electrode array, which means choosing an amplitude threshold, arbitrarily set at 20% of maximum in this study, can be difficult, as small changes in the threshold level would lead to large changes in territory size for each motor unit. The second reason is due to a lack of correlation between the peak amplitude of genioglossus motor units and the size of their estimated territories (Fig. 7). This is in contrast to limb muscles where there is a positive linear relationship between maximum amplitude and territory size (6), albeit a correlation derived from the averages of five different muscles. It is worth noting that regardless of the method used to measure territories, the apparent difference in territory size between expiratory and inspiratory motor units still holds.

The composition of genioglossus motor unit types in healthy individuals varies considerably between studies. With the use of a standardized experimental protocol with participants su-

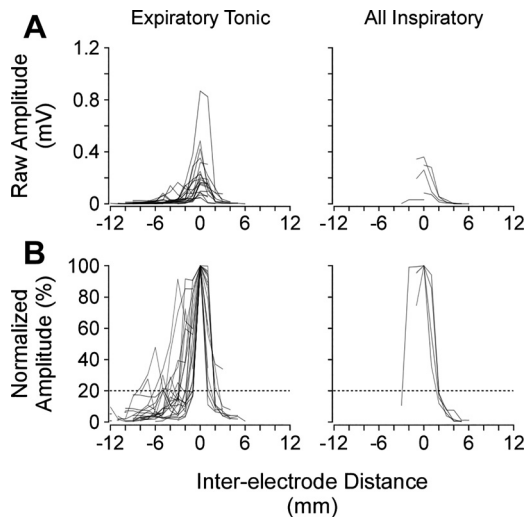


Fig. 6. Estimated territory size relative to peak amplitude. Data are from expiratory tonic and inspiratory motor units showing the peak-to-peak amplitudes from only the spike-triggered averages that contained peaks that crossed the 4-SD threshold. In *A*, the data are centered on the channel with the greatest activity for each motor unit at 0 mm, with the gradient from deep to superficial channels moving from left to right. In *B*, data were normalized to the maximum amplitude for each channel. Note: there was 1 expiratory tonic unit in *B* that only had 1 point  $>20\%$  of maximum amplitude; for this motor unit, territory was calculated as 0.5 mm in the adjusted mean territory.

pine, breathing quietly through a nasal mask, and needles inserted percutaneously below the chin, previous studies have reported inspiratory-related activity in as low as 47% and up to 80% of the population of recorded motor units (21, 24, 25, 34). Expiratory-related activity in these same studies varied between 7 and 29% of recorded motor units. In the present study, there was a larger proportion of expiratory (77%) than inspiratory (17%) motor units. However, the discharge patterns of these motor units were similar to previous studies. For example, peak frequencies for inspiratory tonic units were generally higher than inspiratory phasic units (Fig. 3). Also, the mean tonic and peak frequencies of expiratory tonic units were both comparable with previous findings (24, 25, 34). There are two possible reasons for the high proportion of expiratory motor units in this study. With the use of the multichannel electrode, we were able to sample over a large cross-section of the genioglossus. It appears that the peak activities for expiratory tonic units were

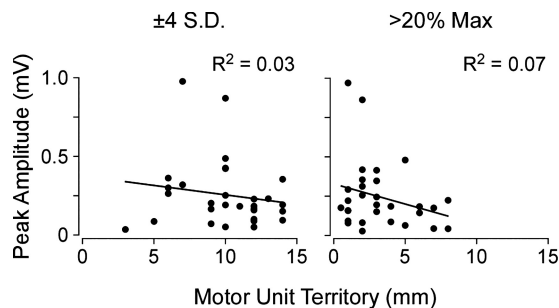


Fig. 7. Correlation between peak amplitude and estimated territory size. Data are shown for all 30 motor units. The relationships between peak amplitude and territory are shown with territory size calculated based on spike-triggered averages with peaks exceeding  $\pm 4$  SD from baseline noise (*left*) or with peak-to-peak amplitudes that were  $>20\%$  of the maximum (Max) across all channels (*right*).

near the superficial border of the genioglossus (Fig. 5*B*), whereas previous studies using monopolar needle or wire recordings avoid this region and target the mid-to-deep fibers of the muscle. The other possibility is that the monopolar recording technique involves locating an active region of the muscle to study, which may have prompted experimenters to position the needle selectively near inspiratory-modulated motor units. However, when sampling over a larger area of the genioglossus, intramuscular wire electrodes record predominantly inspiratory EMG activity in healthy individuals (7, 9, 10). In addition, it is unlikely that the electrodes recorded activity from the more superficial muscle, geniohyoid, which had mainly tonic or no activity in 95% of sites sampled during quiet breathing (5). Although three expiratory tonic units had their peak activities estimated to be below the superficial border of the genioglossus (Fig. 5*B*), the size of their territories suggest they were most likely genioglossus motor units as their territories extended well beyond the physical boundary of the geniohyoid.

Because of the delicate nature of these thin-film multichannel electrodes, a few channels in each electrode array were faulty with the signal dominated by electrical noise (Fig. 5*A*). This tended to occur in the channels near the edges of the electrode arrays, which meant that motor unit territories may have been slightly underestimated across all unit types. Faulty channels also appeared in the middle of several posterior electrodes. For expiratory tonic units, this did not affect the calculation of territory size since measurements were based on the spike-triggered averages of the anterior electrodes from which they were recorded. For inspiratory motor units, however, a series of faulty channels on the posterior electrodes may have affected the true size of their territories. Indeed, it appears in Fig. 6 that inspiratory motor unit territories should be larger if the distribution of their normalized amplitudes were symmetrical about the peak. This may be the case for the single inspiratory unit that had its peak amplitude on the right side of its curve nearest the faulty channels. However, for the remaining four inspiratory units, it seems unlikely that their territories would be much larger than reported here since their normalized amplitudes were approaching 0 (between 0.2 and 1.2% of maximum) next to the faulty channels and their peaks were located in the deepest channels near the physical boundary of the muscle.

In summary, this study estimated the territories of human genioglossus motor units in the anterior and posterior regions of the muscle using a special electrode with multiple recording sites. Genioglossus motor units had large territories with some units spanning the entire cross-section of the muscle. Motor unit territories were larger anteriorly than posteriorly, in line with the large proportion of expiratory units recorded in the anterior electrodes for which territories were more than double the size of posterior inspiratory units. This difference in territory size provides the potential for a more precise and localized motor control of the genioglossus.

#### ACKNOWLEDGMENTS

We thank Associate Prof. Danny J. Eckert for comments on the manuscript.

#### GRANTS

This work was supported by funding through the National Health and Medical Research Council (NHMRC) of Australia. L. E. Bilston, S. C.

Gandevia, and J. E. Butler were supported by NHMRC Research Fellowships. J. P. Saboisky was supported by a NHMRC Career Development Fellowship. S. Muceli and D. Farina were supported by the European Research Council Advanced Grant Decoding the Neural Code of Human Movements for a New Generation of Man-Machine Interfaces (DEMOVE; Contract 267888).

## DISCLOSURES

No conflicts of interest, financial or otherwise, are declared by the authors.

## AUTHOR CONTRIBUTIONS

S.M., D.F., L.E.B., S.C.G., and J.E.B. conceived and designed research; B.L.L., S.M., J.P.S., M.E.H., S.C.G., and J.E.B. performed experiments; B.L.L., S.M., J.P.S., M.E.H., S.C.G., and J.E.B. analyzed data; B.L.L., S.M., J.P.S., M.E.H., S.C.G., and J.E.B. interpreted results of experiments; B.L.L. and J.P.S. prepared figures; B.L.L. drafted manuscript; B.L.L., S.M., J.P.S., D.F., M.E.H., L.E.B., S.C.G., and J.E.B. edited and revised manuscript; B.L.L., S.M., J.P.S., D.F., M.E.H., L.E.B., S.C.G., and J.E.B. approved final version of manuscript.

## REFERENCES

- Bailey EF, Fridel KW, Rice AD. Sleep/wake firing patterns of human genioglossus motor units. *J Neurophysiol* 98: 3284–3291, 2007. doi:10.1152/jn.00865.2007.
- Brennick MJ, Geffer WB, Margulies SS. Mechanical effects of genioglossus muscle stimulation on the pharyngeal airway by MRI in cats. *Respir Physiol Neurobiol* 156: 154–164, 2007. doi:10.1016/j.resp.2006.08.010.
- Brennick MJ, Trouard TP, Gmitro AF, Fregosi RF. MRI study of pharyngeal airway changes during stimulation of the hypoglossal nerve branches in rats. *J Appl Physiol* (1985) 90: 1373–1384, 2001. doi:10.1152/jappl.2001.90.4.1373.
- Brown EC, Cheng S, McKenzie DK, Butler JE, Gandevia SC, Bilston LE. Respiratory movement of upper airway tissue in obstructive sleep apnea. *Sleep (Basel)* 36: 1069–1076, 2013. doi:10.5665/sleep.2812.
- Brown EC, Hudson AL, Butler JE, McKenzie DK, Bilston LE, Gandevia SC. Single motor unit recordings in human geniohyoid reveal minimal respiratory activity during quiet breathing. *J Appl Physiol* (1985) 110: 1054–1059, 2011. doi:10.1152/jappphysiol.00454.2010.
- Buchthal F, Erminio F, Rosenfalck P. Motor unit territory in different human muscles. *Acta Physiol Scand* 45: 72–87, 1959. doi:10.1111/j.1748-1716.1959.tb01678.x.
- Carberry JC, Hensen H, Fisher LP, Saboisky JP, Butler JE, Gandevia SC, Eckert DJ. Mechanisms contributing to the response of upper-airway muscles to changes in airway pressure. *J Appl Physiol* (1985) 118: 1221–1228, 2015. doi:10.1152/jappphysiol.01103.2014.
- Cheng S, Butler JE, Gandevia SC, Bilston LE. Movement of the tongue during normal breathing in awake healthy humans. *J Physiol* 586: 4283–4294, 2008. doi:10.1113/jphysiol.2008.156430.
- Eastwood PR, Allison GT, Shepherd KL, Szollosi I, Hillman DR. Heterogeneous activity of the human genioglossus muscle assessed by multiple bipolar fine-wire electrodes. *J Appl Physiol* (1985) 94: 1849–1858, 2003. doi:10.1152/jappphysiol.01017.2002.
- Eckert DJ, McEvoy RD, George KE, Thomson KJ, Catcheside PG. Genioglossus reflex inhibition to upper-airway negative-pressure stimuli during wakefulness and sleep in healthy males. *J Physiol* 581: 1193–1205, 2007. doi:10.1113/jphysiol.2007.132332.
- Eisele DW, Smith PL, Alam DS, Schwartz AR. Direct hypoglossal nerve stimulation in obstructive sleep apnea. *Arch Otolaryngol Head Neck Surg* 123: 57–61, 1997. doi:10.1001/archotol.1997.01900010067009.
- Fregosi RF. Influence of tongue muscle contraction and dynamic airway pressure on velopharyngeal volume in the rat. *J Appl Physiol* (1985) 104: 682–693, 2008. doi:10.1152/jappphysiol.01043.2007.
- Gallina A, Blouin JS, Ivanova TD, Garland SJ. Regionalization of the stretch reflex in the human vastus medialis. *J Physiol* 595: 4991–5001, 2017. doi:10.1113/JP274458.
- Gootzen TH, Vingerhoets DJ, Stegeman DF. A study of motor unit structure by means of scanning EMG. *Muscle Nerve* 15: 349–357, 1992. doi:10.1002/mus.880150314.
- Héroux ME, Brown HJ, Inglis JT, Siegmund GP, Blouin JS. Motor units in the human medial gastrocnemius muscle are not spatially localized or functionally grouped. *J Physiol* 593: 3711–3726, 2015. doi:10.1113/JP270307.
- Hilton-Brown P, Stålberg E. The motor unit in muscular dystrophy, a single fibre EMG and scanning EMG study. *J Neurol Neurosurg Psychiatry* 46: 981–995, 1983. doi:10.1136/jnnp.46.11.981.
- Kwan BC, Butler JE, Hudson AL, McKenzie DK, Bilston LE, Gandevia SC. A novel ultrasound technique to measure genioglossus movement in vivo. *J Appl Physiol* (1985) 117: 556–562, 2014. doi:10.1152/jappphysiol.01257.2013.
- McGill KC, Lateva ZC, Marateb HR. EMGLAB: an interactive EMG decomposition program. *J Neurosci Methods* 149: 121–133, 2005. doi:10.1016/j.jneumeth.2005.05.015.
- Mu L, Sanders I. Human tongue neuroanatomy: nerve supply and motor endplates. *Clin Anat* 23: 777–791, 2010. doi:10.1002/ca.21011.
- Muceli S, Poppendieck W, Negro F, Yoshida K, Hoffmann KP, Butler JE, Gandevia SC, Farina D. Accurate and representative decoding of the neural drive to muscles in humans with multi-channel intramuscular thin-film electrodes. *J Physiol* 593: 3789–3804, 2015. doi:10.1113/JP270902.
- Nicholas CL, Bei B, Worsnop C, Malhotra A, Jordan AS, Saboisky JP, Chan JK, Duckworth E, White DP, Trinder J. Motor unit recruitment in human genioglossus muscle in response to hypercapnia. *Sleep* 33: 1529–1538, 2010. doi:10.1093/sleep/33.11.1529.
- Oliven A, O’Hearn DJ, Boudewyns A, Odeh M, De Backer W, van de Heyning P, Smith PL, Eisele DW, Allan L, Schneider H, Testerman R, Schwartz AR. Upper airway response to electrical stimulation of the genioglossus in obstructive sleep apnea. *J Appl Physiol* (1985) 95: 2023–2029, 2003. doi:10.1152/jappphysiol.00203.2003.
- Pittman LJ, Bailey EF. Genioglossus and intrinsic electromyographic activities in impeded and unimpeded protrusion tasks. *J Neurophysiol* 101: 276–282, 2009. doi:10.1152/jn.91065.2008.
- Saboisky JP, Butler JE, Fogel RB, Taylor JL, Trinder JA, White DP, Gandevia SC. Tonic and phasic respiratory drives to human genioglossus motoneurons during breathing. *J Neurophysiol* 95: 2213–2221, 2006. doi:10.1152/jn.00940.2005.
- Saboisky JP, Butler JE, McKenzie DK, Gorman RB, Trinder JA, White DP, Gandevia SC. Neural drive to human genioglossus in obstructive sleep apnoea. *J Physiol* 585: 135–146, 2007. doi:10.1113/jphysiol.2007.139584.
- Saboisky JP, Butler JE, Walsh LD, Gandevia SC. New display of the timing and firing frequency of single motor units. *J Neurosci Methods* 162: 287–292, 2007. doi:10.1016/j.jneumeth.2007.01.006.
- Saigusa H, Niimi S, Gotoh T, Yamashita K, Kumada M. Morphological and histochemical studies of the genioglossus muscle. *Ann Otol Rhinol Laryngol* 110: 779–784, 2001. doi:10.1177/000348940111000815.
- Schwartz AR, Eisele DW, Hari A, Testerman R, Erickson D, Smith PL. Electrical stimulation of the lingual musculature in obstructive sleep apnea. *J Appl Physiol* (1985) 81: 643–652, 1996. doi:10.1152/jappl.1996.81.2.643.
- Stålberg E, Antoni L. Electrophysiological cross section of the motor unit. *J Neurol Neurosurg Psychiatry* 43: 469–474, 1980. doi:10.1136/jnnp.43.6.469.
- Stålberg E, Dioszeghy P. Scanning EMG in normal muscle and in neuromuscular disorders. *Electroencephalogr Clin Neurophysiol* 81: 403–416, 1991. doi:10.1016/0168-5597(91)90048-3.
- Takemoto H. Morphological analyses of the human tongue musculature for three-dimensional modeling. *J Speech Lang Hear Res* 44: 95–107, 2001. doi:10.1044/1092-4388(2001)009.
- Tsuiki S, Ono T, Ishiwata Y, Kuroda T. Functional divergence of human genioglossus motor units with respiratory-related activity. *Eur Respir J* 15: 906–910, 2000. doi:10.1034/j.1399-3003.2000.15e16.x.
- Vieira TM, Loram ID, Muceli S, Merletti R, Farina D. Postural activation of the human medial gastrocnemius muscle: are the muscle units spatially localised? *J Physiol* 589: 431–443, 2011. doi:10.1113/jphysiol.2010.201806.
- Wilkinson V, Malhotra A, Nicholas CL, Worsnop C, Jordan AS, Butler JE, Saboisky JP, Gandevia SC, White DP, Trinder J. Discharge patterns of human genioglossus motor units during sleep onset. *Sleep* 31: 525–533, 2008. doi:10.1093/sleep/31.4.525.