

Multiaxial Pulsatile Compliance Changes to the Thoracic Aorta from Before and After TEVAR

Ga-Young Kelly Suh¹, Sarah Cabrerros², John Kim¹, Johan Bondesson³, Jason T. Lee¹, Michael D. Dake⁴, Christopher P. Cheng¹

¹Department of Surgery, ²Department of Mechanical Engineering, Stanford University, ³Department of Mathematical Sciences, Chalmers University of Technology, ⁴Department of Cardiothoracic Surgery, Stanford University



INTRODUCTION

- While thoracic endovascular aortic repair (TEVAR) is commonly employed to treat thoracic aortic diseases, long-term performance of endograft in dynamic aorta remains a concern.
- We aim to quantify multiaxial pulsatile compliance changes to the thoracic aorta from pre- to post-TEVAR.

METHODS

• Study cohort

8 TEVAR patients with acute (n=4) / chronic (n=3) Type B dissections, or chronic arch aneurysm (n=1)

• Geometric data acquisition

1. Cardiac-resolved CTAs were acquired pre- and post-TEVAR (10 frames each).
2. CTA images were loaded to SimVascular, and aortic centerline, surface lines, and cross-sectional lumen were extracted (Figure 1).

• Quantitative analysis

1. Arclengths and longitudinal curvatures (centerline, inner, outer curves) were computed from aortic centerline and surface lines. Diameter was computed from cross-sectional lumen.
2. Deformation was the difference between the minimum and maximum measurements, and incremental change was the difference between adjacent cardiac frames.

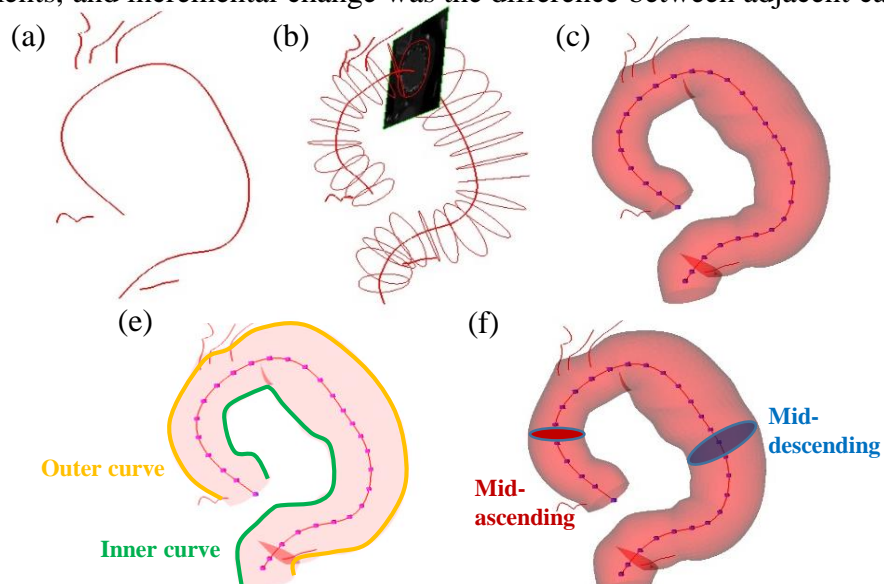


Figure 1. Extraction of aortic geometry: (a) Paths for aorta and vessels based on CT image, (b) Lumen contours segmented along the aorta path, (c) Centerline of aorta formed by lumen contour centroids, (d) Identification of inner and outer curves for curvature measurement, (e) Outer curve, (f) Inner curve, (g) Orthogonal segmentation of mid-ascending and descending lumen for diametric measurement

RESULTS

Deformation (MAX-MIN)	Ascending aorta			Descending aorta		
	Pre-TEVAR	Post-TEVAR	P-value	Pre-TEVAR	Post-TEVAR	P-value
Arclength (%)	6 ± 3	9 ± 4	< 0.05	2 ± 2	2 ± 2	0.70
Inner curvature (cm ⁻¹)	0.10 ± 0.03	0.10 ± 0.05	0.91	0.07 ± 0.06	0.05 ± 0.05	0.53
Center curvature (cm ⁻¹)	0.03 ± 0.01	0.03 ± 0.01	0.34	0.02 ± 0.01	0.02 ± 0.01	0.10
Outer curvature (cm ⁻¹)	0.05 ± 0.04	0.06 ± 0.08	0.54	0.04 ± 0.05	0.03 ± 0.04	< 0.05
Diameter (%)	6 ± 3	6 ± 3	0.96	8 ± 3	6 ± 4	< 0.05

Table 1. Deformation of ascending and descending aorta at pre- and post-TEVAR, and significance from pre vs. post-TEVAR.

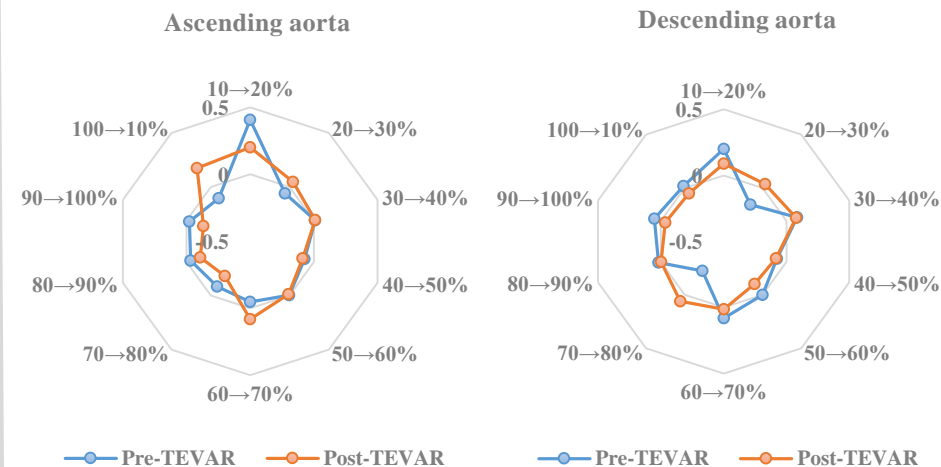


Figure 2. Incremental change of aortic arclength during a cardiac cycle at pre- and post-TEVAR

- From pre- to post-TEVAR, the ascending aorta increased arclength deformation. The descending aorta exhibited unchanged arclength deformation but decreased curvature and diametric deformation (Table 1).

- For the ascending aorta, the greatest incremental change in arclength occurred between 10~20% cardiac frames (Figure 2).

DISCUSSION

- TEVAR decreased bending and diametric deformations of the descending aorta while it increased axial deformation of the ascending aorta. This may be due to the increased stiffness and oversizing by the endograft, causing damping of deformation at the stented region and increased deformation of the unstented region.
- The thoracic aorta exhibits time-dependent multiaxial deformations, and the mechanical impact of TEVAR are critical to improve device design.